CPQ Orthopaedics (2019) 3:4
Prospective Comparative Randomised Clinical Trial

Surgical Management of Unstable Pertrochanteric Fractures: Prospective Comparative Study Between Gamma™ Nail and Dynamic Hip Screw Plate of 36 Cases

Bouabdellah, M.[1*], Bouzidi, R.[1], Ammar, A.[2], Hadhri, K.[1], Lebib, H.[1] & Kooli, M.[1]

[1]*Department of Orthopedic and Traumatology of Charles Nicolles Tunis*

[2]*Institute of Orthopedic Surgery Mohamed Taieb Kassab Manouba, University Tunis Elmanar*

[*]**Correspondence to:** Dr. Bouabdellah, M., Department of Orthopedic and Traumatology of Charles Nicolles Tunis.

Received: 25 September 2019

Published: 30 September 2019

Keywords: *Per Trochanteric; Fracture; Dynamic Screw Plate; Intramedullary Fixation*

Abstract

Purpose of the Study

The objective of this study was to evaluate and to compare the dynamic hip screw and intramedullary Gamma™ nail fixation for the treatment of pertrochanteric fracture in terms of stability, complications and cost effectiveness.

Material and Methods

This prospective randomized study included 36 patients hospitalized in an emergency setting for instable per trochanteric fracture next term between June 2018 and December 2018. Two fixation systems were used: the Gamma™ proximal femoral nail and the screw plate dynamic hip screw DHS. We noted: operative data (type of implant, duration of surgical procedure), postoperative data (blood loss, radiographic findings, early complications), and outcome mortality and radiographic

results. All patients were assessed least six months after surgery. The series included 36 patients, 16 men and 20 women. The Gamma™ nail was used for 15 patients and the DHS for 21. The AO classification was: A2 1= 11, A2 2 =10, A2 3 =4, A3 1 =3, A3 2 =2, A3 3= 6. All this fractures were unstable.

Results

Mean operative time was 125 minutes for intramedullary nailing and 92 minutes for screw plate fixation (0. 004). Mean blood loss was 55ml for intramedullary nailing and 800ml for screw plate fixation (p = 0.006). The mean hospital stays were 11 days in Gamma™ nail group and 12.5 in DHS group. At six months, no mechanical complication was involved in the two groups, such as migration of the cervical screw outside the femoral head. Three deaths occurred in the intramedullary nailing group, and one in the DHS group.

Discussion and Conclusion

Data in the literature report an advantage for intramedullary nailing, particularly a mechanical advantage, for the treatment of per trochanteric fractures. Our findings show similar results with less bleeding and earlier charge in the Gamma™ nail group.

Introduction

The trochanteric fractures are the most common of the elderly; they maintain a high mortality rate [1]. They are a public health problem, especially with the increase in life expectancy and the risk of osteoporosis. The number of fractures of the upper extremity of the femur is expected to increase from 1.7 million in 1990 to 6.25 million in 2025. These figures give some idea of the magnitude of the problem, which has an international dimension [2-4].

The frailty of these elderly patients makes it necessary to reduce the risk of surgical complications. Various means of osteosynthesis have been developed to treat these fractures: screw plate DHS, THS, nail with centro-medullary support: Gamma™, PFN ... [5]. The aim of this study is to evaluate the morbidity of surgical treatment of unstable per trochanteric fractures and to compare a support material on the lateral cortical of the femur: the DHS (Dynamic Hip Screw) and an endo-medullary material with cephalic anchor screws: the Gamma™ nail, both of which are commonly used in this indication. The evaluation of the perioperative parameters, stability, complications, and cost/effectiveness were sought.

Material and Method

This is a prospective, randomized study, including 36 patients, hospitalized in emergency for unstable pertochanteric fractures in the department of orthopedics and traumatology of Charles Nicolle Hospital in Tunis, Tunisia, between June 2018 and December 2018. The randomization was performed consecutively by a random table. All measurements were performed by a single investigator.

The inclusion criteria were: patients who arrived in emergency for a fracture of the trochanteric region classified A2 or A3 according to the AO classification [6]. (Fig. 1) with an ASA score [7] less than or equal to 4.

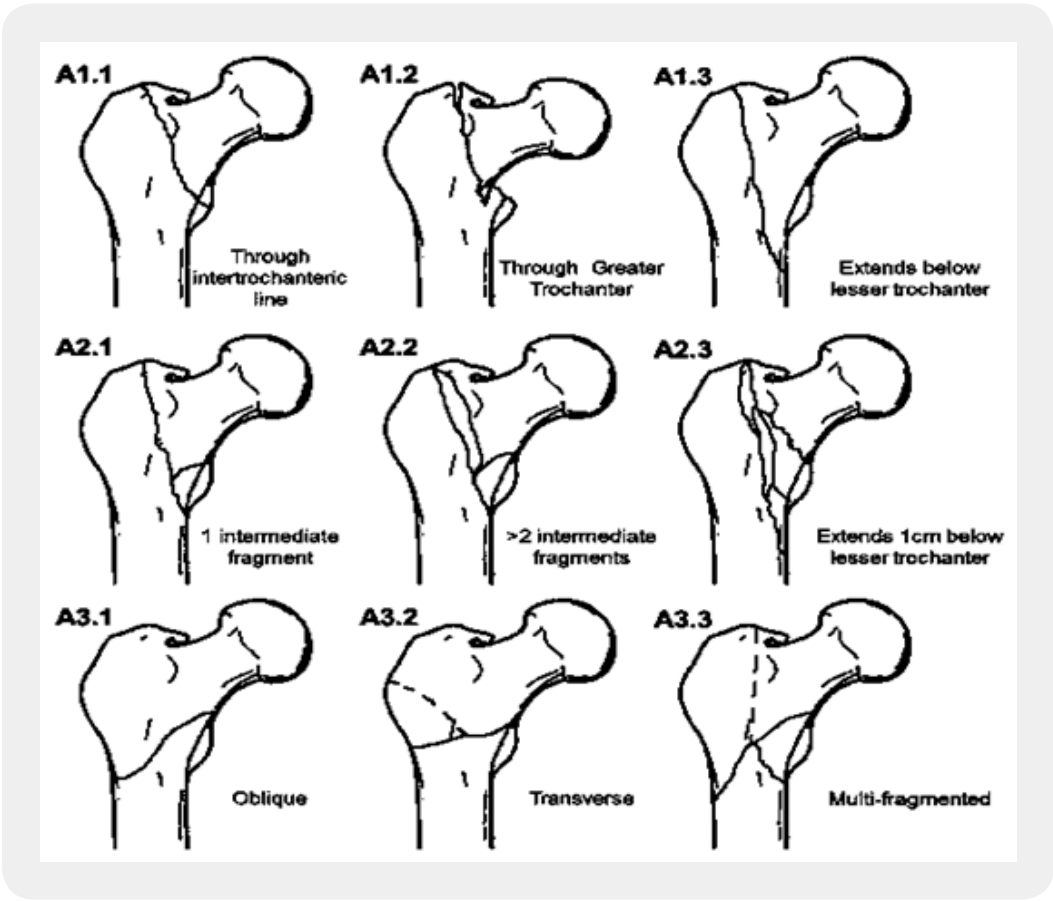

Figure 1: *Pertochanteric fractures: AO classification*

The exclusion criteria were: senile dementia, non-autonomous patients before the trauma, A1 type fractures according to the AO classification, and ASA scores from 5 to 6.

Two osteosynthesis techniques were performed: the Gamma™ nail and the DHS screw plate. Preoperative assessment included: sex, age, search of a chronic disease and ASA score. The fractures were classified according to the AO classification. The criteria of judgment between the two techniques of osteosynthesis were: the duration of the intervention, the anatomical character or not of reduction according to the criteria of Baumgaertner (anatomical or acceptable) [8]. The quantity of blood collected by the aspiration drain, the immediate postoperative complications, the duration of stay in hospital and the recovery time of weight bearing.

At six months postoperatively, the mortality rate and late mechanical complications were assessed. The statistical analysis of the different variables was performed using Statistic Package for Social Sciences (SPSS).

Differences were considered to be statistically significant when P<0.05. The chi-square test was used to compare differences between the two techniques for each variable, and the Student's t-test was used for quantitative variables.

Results

Thirty-six patients were included: 20 women and 16 men. The average age of the patients was 75 (62 to 88 years). 15 fractures were fixed by Gamma™ nail (9 women and 6 men), and 21 by DHS (11 women and 10 men). Twenty-eight patients (77%) had one or more chronic medical disease.

The average operating time for Gamma™ nails was 125 minutes and 92 minutes for DHS. According to the criteria of Baumgaertner, the reduction obtained was judged anatomical in 11cases (73%) and non-anatomical but acceptable in 4 cases for Gamma™ nails. For DHS, it was anatomical in 16 cases (76%) and acceptable in 5 cases. Mean blood loss was 550ml with Gamma™ nails and 800ml with DHS with significant difference (0.004).

The length of stay was on average 10.5 (± 3) days for Gamma™ nails and 12.6 (± 2) days for DHS with a non-significant difference (0.02).

The resumption of the weight bearing was carried out, on average at the 28th day for the Gamma™ nail, and at the 53rd day for the DHS. These complications included deep vein thrombosis, two Escher, urinary tract infection, three anemia, pulmonary embolism, neuropsychiatric disorders, and stroke with right hemiplegia. Comparison between the two groups seems difficult. However, in absolute numbers, the overall complications for DHS were 8 for 21 patients (38%) and 2 for 15 (13%) patients treated with Gamma™nail, without prejudging their severity. An immediate postoperative death by ventricular tachycardia complicated by cardiac arrest in a patient operated by Gamma™nail was noted (Table 1).

Table 1: *General Postoperative Complications*

General Complication	DHS	Gamma™ nail
Thrombosis leg	1	0
Escher	2	0
Urinary infection	1	0
Anemia for which transfusion	3	0
Pulmonary embolism	1	0
Neuropsychiatric disorders	0	1
Cerebral vascular accident	0	1
Post operative death	0	1

Local complications were more common with DHS, but some of these complications did not result in functional repercussions. The complications encountered were wound infection treated with surgical drainage and adapted antibiotic therapy in a patient treated with DHS.

Unexplained residual pain, persistent in one case treated with DHS and a case treated with Gamma™ nail (Table 2)

Table 2: *General Postoperative Complications*

Local Complication	DHS	Gamma™nail
Wound infection	2	0
Unexplained residual pain	1	1

At six months, the mortality rate was 3 cases in the Gamma™ nail group and 1 case in the DHS group. Mechanically, no displacement of the cervical screw or axial migration was noted in both groups. The parameters of stability and consolidation are presented in Table 3.

Table 3: *General Postoperative Complications*

Secondary Outcome and mechanical parameters	DHS	Gamma™ nail
-Sitting on the chair (days)	1.5	1.25
-Partial weight bearing (days)	53 (+- 6)	(28+-4)
-Mechanical complication		
Lateral migration	0	0
Axial migration inferior to 1cm	4	2
Caputcollum-diaphyseal (CCD) angle at 3 months	125+- 4°	123+- 5°
Fracture under implant	0	1(at 3months post-operative) Revision by longer Gamma™ nail
- Non union	0	0

Discussions

The trochanteric fractures are a major cause of mortality and morbidity and functional loss in the elderly. Their morbidity is closely related to the degree of fracture instability and comminution as well as the quality of reduction and osteosynthesis. Many devices have been described in the treatment of pertrochanteric fractures [9-12]. Many studies have compared the Gamma™ nail, to screw plate systems.

At first, the Gamma™ nail seemed to provide better results: shorter operating time, less bleeding and earlier weight bearing compared to external plate systems [13].

Nailing seems to have a theoretical advantage in reducing bleeding, the risk of sepsis, and the risk of tissue damage and the time of surgical procedure compared with direct open surgical techniques. At last follow-up, the clinical and radiographic results are equivalent [14].

Many study showed better functional results in the Gamma™ nail group compared to the DHS group. This was due to the minimally invasive approach, reduced pain, with a quick chair setting [15,16].

These results were confirmed by a meta-analysis published by Ma KL [17] comprising 14 studies with 1 983 patients comparing nailing versus the outer plate. On the other side, this meta-analysis reports a greater risk of femoral shaft fracture with intramedullary nailing. Similarly ,Yeganeh *et al.* [18] showed clinical and radiographic superiority with lower bleeding and earlier weight bearing of PFN nail compared to DHS screw plate . Calderón *et al.* [19] reported the superiority of the nail in a shorter time of surgical procedure and postoperative pain, less bleeding and earlier weight bearing. On the other hand, the clinical and radiographic results were equivalent in the long term.

Nevertheless, level I studies have reported different conclusions. Ahrengart *et al.* [20] showed in a study out of 426 patients an increased operative time and bleeding for the Gamma™ nail.

The classic complications of the Gamma™ nail mentioned in many publications were intraoperative fractures of the greater trochanter, caused by the large metaphyseal diameter of the implant as well as fractures under the nail [17,21-24]. And Svenson *et al.* [25] showed a higher rate of surgical revision in the Gamma™ groups for secondary displacement of the fracture or fracture under the nail. Finally, Adams *et al.* [14] showed that, despite the greater stability of the Gamma™ nail compared to the screw plate, the difficulties of optimal positioning of the cephalic screw with increased risk of secondary displacement type and its characteristic complications (diaphyseal fractures, trochanteric rests). For this reason, its superiority over the screw plate was not admitted.

A stress fracture of the nail can occur especially when the fracture is pathological or unstable with a subtrochanteric component [26].

Open direct approach osteosynthesis has the theoretical advantage of allowing anatomical reduction, with the disadvantage of additional devascularization of the fracture site and increased bleeding and infectious risk. Moreover, this method does not allow an optimal fixation of unstable fractures and therefore does not always allow early weight bearing with complete safety [27-29].

The use of the DHS screw plate is a reliable and simple method for the synthesis of pertrochanteric fractures [30]. Oger *et al.*, with 84 fractures in 82 patients, found 100% consolidation and 4.8% mechanical complications (sweeping and disassembly of the plate). The sliding of the screw is more important in unstable fractures and this despite deferred weight bearing.

A study by Kaiser *et al.* [31], on 24 human cadavers, shows a greater deformation of the DHS compared to the Gamma™ nail. On the other hand, this rigidity is accompanied by a higher degree of femoral diaphyseal fracture. For open osteosynthesis, the use of locked compression plates could improve mechanical stability. Indeed, in a prospective randomized comparative study between PFN nail and proximal femoral locked plate (PFLCP), Singh *et al.* [32] found equivalent clinical and radiographic results in the treatment of unstable trochanteric fractures at 2 years of follow-up.

Biomechanical tests on cadavers have also been performed by Haynes *et al.* [33], to analyze the phenomenon of cervico-cephalic screw scanning. The larger diameter of its screw shows that the use of Gamma™ nail seems to reduce the risk of sweeping compared to DHS.

Butt *et al.* [34] compared Gamma™ nail and DHS in a prospective study and reported a number of larger complications with Gamma™ nail, particularly femur fractures.

The rate of cut-out migration for first-generation nails averaged 3.1% according to Parker *et al.* [35].

Hoffmann *et al.* [36] found no significant difference in the management of pertrochanteric fractures between the Gamma™ nail and DHS.

In their meta-analysis, of all the randomized trials published comparing Gamma™ nail and DHS screw plate, Parker *et al.* [35] do not recommend using Gamma™ nail for trochanteric fractures. They showed that the Gamma™ nail significantly increased the risk of femoral fracture as well as the number of surgical revisions. Similarly, in a retrospective study of 1314 proximal femur fractures, Muller [37] found a greater number of fractures under nail PFN (2.1%) compared to DHS (0.5%). In our study, we noted one case of fracture under a Gamma™ nail which required its revision by a long Gamma™ nail.

Conclusions

Fractures of trochanteric region have an increasing incidence, with significant socio-economic impact. The operative technique and the choice of the implant influence the functional and radiographic result. They must essentially take into account whether the fracture is stable or not. The analysis of the literature shows an advantage to the intramedullary nail in the short term, despite the risk of femoral fracture on nail. Our study found no significant difference in bone consolidation and functional outcome at last follow-up, but it confirms the superiority of Gamma™ nail in postoperative, due to lesser bleeding and earlier weight bearing.

Conflict of Interest

The authors declare that there is no conflict of interest relevant to this article.

Bibliography

1. Saltzherr, T. P., Borghans, H. J., Bakker, R. H. & Go, P. M. (2006). Proximal femur fractures in the elderly in The Netherlands during the period 1991-2004. incidence, mortality, length of hospital stay and an estimate of the care capacity needed in the future. *Ned Tijdschr Geneesk., 150*(47), 2599-2604.

2. Hommel, A., Ulander, K., Bjorkelund, K. B., Norrman, P. O., Wingstrand, H. & Thorngren, K. G. (2008). Influence of optimised treatment of people with hip fracture on time to operation, length of hospital stay, reoperations and mortality within 1 year. *Injury., 39*(10), 1164-1174.

3. Haleem, S., Lutchman, L., Mayahi, R., Grice, J. E. & Parker, M. J.(2008). Mortality following hip fracture: trends and geographical variations over the last 40 years. *Injury., 39*(10), 1157-1163.

4. Baudoin, C. (1997). Epidemiology and economic impact of the proximal femoral fracture: Fractures of the proximal femur. *Press Med., 26,* 1449-1459.

5. Arirachakaran, A., Amphansap, T., Thanindratarn, P., Piyapittayanun, P., Srisawat, P. & Kongtharvonskul, J. (2017). Comparative outcome of PFNA, Gamma nails, P.C.C.P., Medoff plate, L.I.S.S., and dynamic hip screws for fixation in elderly trochanteric fractures: a systematic review and network meta-analysis of randomized controlled trials. *Eur J Orthop Surg Traumatol., 27*(7), 937-952.

6. Muller, M. E., Nazarian, S., Koch, P. & Schatzker, J. (1990). The Comprehensive Classification of Fractures of Long Bones/AO Classification of Fractures Springer, Berlin.

7. American Society of Anesthesiologists. ASA physical status classification system.

8. Baumgaertner, M. R., Curtin, S. L., Linskog, D. M. & Keggi, J. M. (1995). The value of the tip-apex distance in predicting failure of fixation of peritrochanteric fractures of the hip. *J Bone Joint Surg Am., 77*(7), 1058-1064.

9. Barnes, B. & Dunovan, K.(1987). Functional outcomes after hip fracture. *Phys Ther ., 67*(11), 1675-1679.

10. Bejui, J. B., Ostéosynthèse des fractures trochantériennes. (1994). Cahier d'enseignement de la Sofcot. Paris. *Expansion scientifique Française.,* 1-17.

11. Socci, A. R., Casemyr, N. E., Leslie, M. P. & Baumgaertner, M. R. (2017). Implant options for the treatment of intertrochanteric fractures of the hip: rationale, evidence, and recommendations. *Bone Joint J., 99-B*(1), 128-133.

12. van Leur, J. P. H., Jakma, T. S. C., Willemsen, S. P. & Punt, B. J. (2019). Trochanteric Fixation Nail® with Helical Blade Compared with Femoral Neck Screw for Operative Treatment of Intertrochanteric Femoral Fractures. *Hip Pelvis., 31*(1), 48-56.

13. Lahoud, J. C., Asselineau, A., Salengro, S., Molina, V. & Bombart, M. (1999). Comparative study of gamma nail and nail, blade or screw plates for subtrochanteric fractures treatment. *J Bone Joint Surg (Br)., 81,* 350.

14. Lorich, D. G., Geller, D. S. & Nilson, J. H. (2004). Osteoporotic pertrochanteric hip fractures, management and current controversies. *Instr Course Lect., 53,* 441-454.

15. Giraud, B., Dehoux, E., Jovenin, N., Madi, K., Harisboure, A., Usandizaga, G. & Segal, P. (2005). Comparaison vis-plaque dynamique et ostéosynthèse intra-médullaire antérograde dans les fractures pertrochantériennes; Une étude prospective randomisée. *Rev Chir Orth., 91,* 732-736.

16. Yu, X., Wang, H., Duan, X., Liu, M. & Xiang, Z. (2018). Intramedullary versus extramedullary internal fixation for unstable intertrochanteric fracture, a meta-analysis. *Acta Orthop Traumatol Turc., 52*(4), 299-307.

17. Ma, K. L., Wang, X., Luan, F. J., Xu, H. T., Fang, Y., Min, J., Luan, H. X., Yang, F., Zheng, H. & He, S. J. (2014). Proximal femoral nails antirotation, Gamma nails, and dynamic hip screws for fixation of intertrochanteric fractures of femur: A meta-analysis. *Orthop Traumatol Surg Res., 100*(8), 859-866.

18. Yeganeh, A., Taghavi, R. & Moghtadaei, M.(2016). Comparing the Intramedullary Nailing Method Versus Dynamic Hip Screw in Treatment of Unstable Intertrochanteric Fractures. *Med Arch., 70*(1), 53-56.

19. Calderón, A., Ramos, T., Vilchez, F., Mendoza-Lemus, O., Peña, V., Cárdenas-Estrada, E. & Acosta-Olivo, C. (2013). Proximal femoral intramedullary nail versus DHS plate for the treatment of intertrochanteric fractures. A prospective analysis. *Acta Ortop Mex., 27*(4), 236-239.

20. Ahrengart, L., Tornkvist, H., Fornander, P., Thorngren, K. G., Pasanen, L. & Wahlstrom, P. (2002). A randomized study of the compression hip screw and gamma nail in 426 fractures. *Clin Orthop Relat Res.,* (401), 209-222.

21. Adams, C. I., Robinson, C. M., Court-Brown, C. M. & McQueen, M. M. (2001). Prospective randomized controlled trial of an intramedullary nail versus dynamic screw and plate for intertrochanteric fractures of the femur. *J Orthop Trauma., 15*(6), 394-400.

22. Bridle, S. H., Patel, A. D., Bircher, M. & Calvert, P. T. (1991). Fixation of intertrochanteric fractures of the femur. A randomized prospective comparison of the Gamma nail and dynamic hip screw. *J Bone Joint Surg (Br)., 73*(2), 330-334.

23. Aune, A. K., Ekeland, A., Grøgaard, B., Ødegaard, B. & Alho, A. (1994). Gamma nail vs compression screw for trochanteric femoral fractures: 15 reoperations in a prospective, randomized study of 378 patients. *Acta Orthop Scand., 65*(2), 127-130.

24. Radford, P. J., Needof, M. & Webb, J. K. (1993). A prospective randomised comparison of the dynamic hip screw and the Gamma locking nail. *J Bone Joint Surg (Br)., 75*(5), 789-793.

25. Svenson, O., Andersen, M., Poulsen, T., Nymark ,T., Overgaard, S. & Rock, N. D.(2006). The trochanteric gamma nail versus the dynamic hip screw: a prospective randomised study. One-year follow-up of 146 intertrochanteric fractures. *Hip Int., 16*(4), 293-298.

26. Mnif, H., Koubaa, M., Zrig, M., Trabelsi, R. & Abid, A. (2009). Mortalité et morbidité après fracture trochantérienne chez les personnes âgées. Étude prospective de 100 cas . *Rev Chir Orth., 95*(7), 609-615.

27. Cooper, C., Campion, G. & Melton, L. G. (1992). Hip fractures in the elderly: a worldwide projection. *Osteporos Int., 2*(6), 285-289.

28. Kempf, I. & Bitar, S. (1990). Place et limites de la méthode d'Ender modifiée avec verrouillage coulissant dans le traitement des fractures trochantériennes du fémur. In: Duparc J, editor. Enclouage centromédullaire, cahiers d'enseignement de la Sofcot no 39. Paris: Expansion Scientifique Française., 38-46.

29. Putz, P., Coussaert, E., Delvaux, D., Long Pertz, P., Thys, R. & Cantraine, F. (1190). Ostéosynthèse des lésions proximales du fémur par vis-plaque dynamisée. *Int Orthop., 14,* 285-292.

30. Oger, P., Katz, V., Lecorre, N. & Beaulils, P. (1998). Fractures du massif trochantérien traitées par vis plaque DHS : mesure du glissement selon le type anatomique de fracture. *Rev Chir Orthop., 84,* 539-545.

31. Kaiser, W., Burmester, J., Hausmann, H., Guliemos, V., Hatzel, H. J. & Merker, H. J. (1997). Comparison of gamma nail and DHS on stability concerning unstable pertrochanteric femur osteotomies. *Langenbecks Arch Chir., 382,* 100-106.

32. Singh, A. K., Narsaria, N., G. R. A. & Srivastava, V. (2017). Treatment of Unstable Trochanteric Femur Fractures: Proximal Femur Nail Versus Proximal Femur Locking Compression Plate. *Am J Orthop (Belle Mead NJ)., 46*(2), 116-123.

33. Haynes, R. C., Poll, R. G., Miles, A. W. & Weston, R. B. (1997). Failure of femoral head fixation: a cadaveric analysis of lag screw cutout with the gamma locking nail and AO dynamic hip screw. *Injury., 28*(5-6), 337-341.

34. Butt, M. S., Kriskler, S. J., Nafie, S. & Ali, M. S.(1995). Comparison of dynamic hip screw and gamma nail: a prospective, randomized, controlled trial. *Injury., 26*(9), 615-618.

35. Parker, M. J. & Pryor, G. A. (1996). Gamma versus DHS nailing for extracapsular femoral fractures. Meta-analysis of ten randomised trials. *Int Orthop., 20*(3), 163-168.

36. Hoffmann, R., Scmidmaier, G., Schulz, R., Schutz, M. & Sudkamp, N. P. (1999). Classic nail versus DHS. A prospective study on operative fixation of trochanteric femur fractures. *Unfallchirurg., 102*(3), 182-190.

37. Müller, F., Galler, M., Zellner, M., Bäuml, C., Marzouk, A. & Füchtmeier, B. (2016). Peri-implant femoral fractures: The risk is more than three times higher within PFN compared with DHS. *Injury., 47*(10), 2189-2194.